



Incidence and Risk Factors of Leukoaraiosis in Geriatric Patients: A Retrospective Study

Abdurrahman Sönmezler^{1*}, Tahir Kurtuluş Yoldaş², Ekrem Karakaş³, Serkan Topçu⁴ and Şakir Özgür Keşkek⁵

¹Department of Neurology, Adana City Research and Training Hospital, Adana, Turkey

²Department of Neurology, Ankara Yıldırım Beyazıt Uni.; Faculty of Medicine, Üniversiteler Mah. İhsan Doğramacı Bulvarı Ankara Atatürk Eğitim Araştırma Hastanesi Yanı Bilkent Çankaya, Ankara, Turkey

³Department of Radiology, Faculty of Medicine, Harran University, Sanliurfa, Turkey

⁴Department of Neurology, Faculty of Medicine, Harran University, Sanliurfa, Turkey

⁵Department of Internal Medicine, Adana Şehir Research and Training Hospital, Adana, Turkey

Article info

Received 26 February 2019

Revised 25 March 2019

Published 05 April 2019

*Corresponding author: Dr. Abdurrahman Sönmezler (Ass. Prof), Department of Neurology, Adana City Research and Training Hospital, Adana, Turkey; E-mail: sonmezlera@gmail.com

Abstract

Background: Lexical meaning of leukoaraiosis is the decrease of density in white matter. Conceptually, the term leukoaraiosis does not reflect a clinical presentation but a radiological one. Proliferation of the clinical use of computed tomography (CT) scan of the head and MRI (magnetic resonance imaging) helps the easy diagnosis of leukoaraiosis. In this study, we aimed to investigate the frequency of leukoaraiosis in the geriatric population in our region.

Methods: Retrospective study in the Harran University Medical Faculty Neurology Department between 2011 and 2013. 339 out of 379 geriatric cases treated as outpatients were taken.

Results: The average age of 155 male and 224 female subjects is 68.3 ± 6.3 . There was no leukoaraiosis in 57 cases. In 282 cases leukoaraiosis was observed. Those with leukoaraiosis; 74 cases (26.2%) stage 1, 52 cases (18.4%) stage 2, 54 cases (19.1%) stage 3, 45 cases (16.0%) stage 4. There was a significant correlation between age and leukoaraiosis phase. As age increased, the stage increased ($p < 0.0001$). There was a significant correlation between cerebrovascular disease and leukoaraiosis phase ($p = 0.0067$).

Conclusions: As a result, it is noteworthy that leukoaraiosis increases in the geriatric population. There was a significant correlation between leukoaraiosis phase with mild atrophy, severe atrophy and cerebrovascular disease.

Keywords: Magnetic Resonance Imaging; Leukoaraiosis; Geriatric patient

Introduction

Leukoaraiosis is defined as low-density areas in the white matter, diffuse or locally visible, often symmetrically located, with poorly defined borders, localized at the corners of the lateral ventricles and in the centrum semiovale. Leukoaraiosis refers radiologic appearance. It has begun to be recognized by the clinical use of the CT (computerized tomography) and MRI (magnetic resonance imaging) [1]. It has been reported that leukoaraiosis is not only a radiological diagnosis, it

does not reflect a clinical impression, it can also be seen in a normal elderly population without any neurological findings [2,3]. In this study, we aimed to investigate the frequency of leukoaraiosis in the geriatric population in our region.

Methodology

339 out of 379 cases treated as outpatients in Harran University Medical Faculty Neurology Department

between 2011 and 2013 were taken. The average age of 155 male and 224 female subjects is 68.3 ± 6.3 .

The MRI studies were graded for the extent and severity of white matter lesions on a 0–4 scale according to Brant-Zawadzki et al. [4]. Grade 0 was assigned when no such lesions were evident. Grade 1 indicated punctated foci of high signal intensity in the white matter immediately at the top of the frontal horns of the lateral ventricles. Grade 2 was assigned when the white matter lesions were seen elsewhere but remained confined to the immediate subependymal region of the ventricles. Grade 3 indicated periventricular as well as separate, discrete, deep white matter foci of signal abnormality. Grade 4 was reserved for those cases in which the discrete white matter foci had become large and coalescent. The associations between the accompanying diseases and leukoaraiosis were investigated.

The MedCalc 15.8 software program (MedCalc Belgium) was used for statistical analysis. Data were reported as the mean \pm standard deviation. Kolmogorov-Smirnov test was used to show the normal distribution of quantitative measurements. Chi-square is used to test the statistical significance of differences. The ANOVA test was used to compare the quantitative measurements between the groups more than two. Post-hoc test (Scheffé’s test) was used for pairwise comparison of subgroups, when the ANOVA test was positive. Spearman’s correlation coefficient was used to analyse the degree of association between two variables. Multiple regression test (backward method) was used to analyse the relationship between a dependent variable and one or more independent variables (predictor variables or explanatory variables). The probability of making a Type I error (alpha, significance) is 0.05 in all tests.

Table 1: Leukoaraiosis phase percentages of cases.

Phase	N	%
Phase 0	57	16.8
Phase 1	74	26.2
Phase 2	52	18.4
Phase 3	54	19.1
Phase 4	45	16.0

Results

155-man (40.9%, average age 68.6 ± 6.1) and 224 women (mean age 68.1 ± 6.5 59.1) cases were evaluated. 339 cases included in the study. There was no leukoaraiosis in 57 cases. In 282 cases leukoaraiosis

was observed. Those with leukoaraiosis; 74 cases (26.2%) stage 1, 52 cases (18.4%) stage 2, 54 cases (19.1%) stage 3, 45 cases (16.0%) stage 4 (**Table 1**), (**Figure 1**).

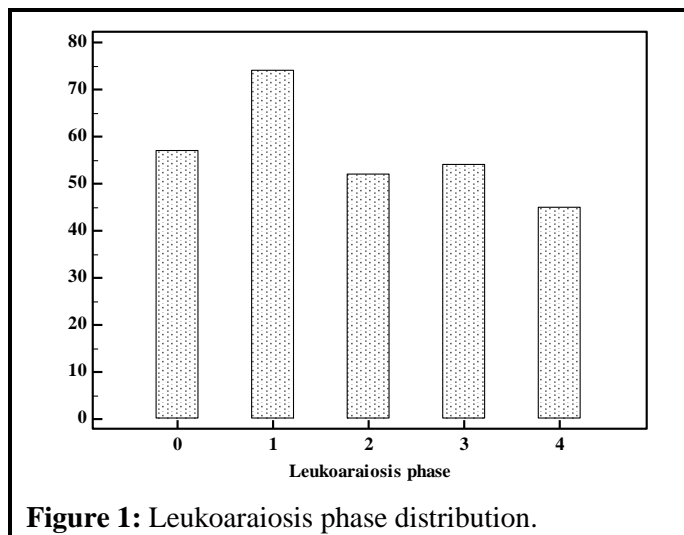


Figure 1: Leukoaraiosis phase distribution.

Vertigo 71, cerebrovascular disease 99, atypical headache 41, dementia 15, sleep apnea 7, migraine 7, parkinson 12, vascular headache 18, epilepsy 10, tension headache 51, tremor 4, ischemic optic neuropathy 3, trigeminal neuralgia 3, hemifacial spasm 1, Neurobehçet 1, demyelinating disease was observed in the 5 case. There was a significant correlation between age and leukoaraiosis phase. As age increased, the stage increased ($p < 0.0001$) (**Figure 2**).

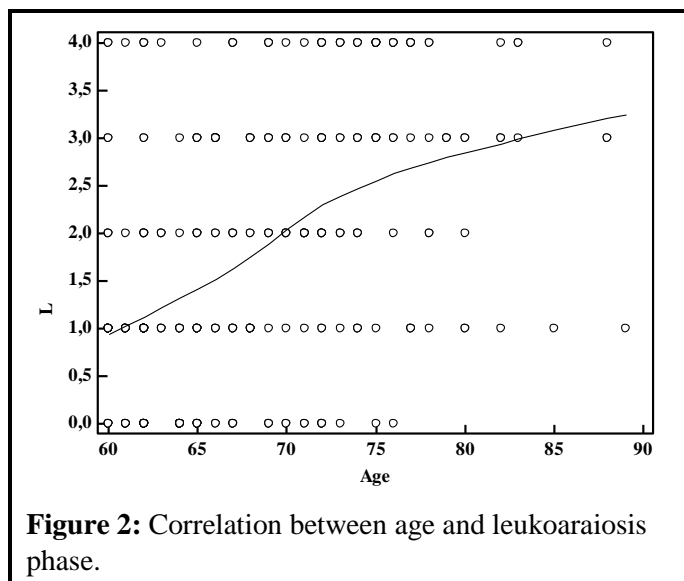
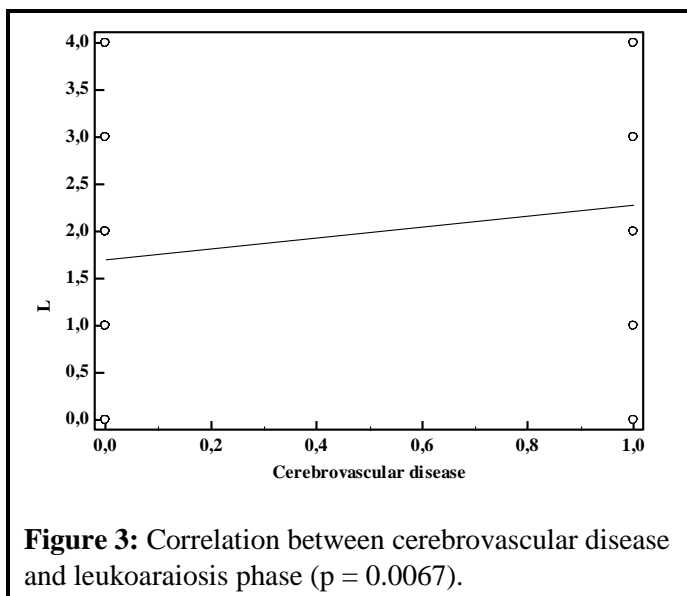


Figure 2: Correlation between age and leukoaraiosis phase.

There was a higher grade in males and a lower degree in females between gender and leukoaraiosis grade ($p = 0.002$, $r = -0.183$). There was a negative correlation between tension type headache and leukoaraiosis phase

($p=0.0297$, $r=-0.1131$). There was a significant correlation between cerebrovascular disease and leukoaraiosis phase ($p=0.0067$) (**Figure 3**). There was a significant correlation between mild atrophy and severe atrophy and leukoaraiosis phase on MRI ($p<0.0001$). No statistically significant correlation was found between leukoaraiosis and other diseases. In multiple regression analysis; leukoaraiosis phase associated with age, severe atrophy, mild atrophy, trigeminal neuralgia, and dementia.



Discussion

Goto et al. from Japan [5] found the leukoaraiosis frequency to be 5% among 4742 scans analyzed within 2.5 years. Kinkel et al. from North America [6] have reported that out of the 1633 adult cases analyzed in five months, only 1.7% had leukoaraiosis. The results of a neuropathology study carried out by Lotz et al. [7] provided some data concerning the frequency of white matter disorder. Accordingly, the rate of density reduction in periventricular white substance identified in the autopsy of 202 cases is determined as 12.4%. The leukoaraiosis rate identified in 59 years old or older and mentally stable people via CT head scan has been reported as 8.6% and 10.9% in two different studies [1,8]. This white matter changes increase through aging in both healthy groups and patients [7-9]. Rotterdam Study [9] identified the leukoaraiosis frequency as 27% looking at the MRIs of healthy individuals at the age of 65-84. Based on these findings, age can be considered as an important factor causing the decrease of white matter. In fact, such white matter changes are now being called as 'white matter changes associated with age' [10]. Inzitari et al. who carried out the first study on the

subject [8] reported that the frequency and severity of leukoaraiosis increased with aging, and this data was verified by subsequent studies as well [9-13]. Both the studies based on population screening [9] and the studies in stroke cases [11,12] demonstrated that leukoaraiosis age relationship is valid for all cases with or without dementia. Hijdra et al., who investigated the prevalence of leukoaraiosis in different types of strokes (1990), detected leukoaraiosis in 38% of all stroke patients, and saw this finding the most often in small artery disease and deep intracerebral hemorrhage. In the Lozan stroke study [12], the leukoaraiosis frequency in acute ischemic stroke was found to be 6.8% and the authors reported that leukoaraiosis was most often detected in the subcortical and lacunar infarcts. Aging, chronic hypertension and diabetes leads to the arteriolosclerosis changes in the small-scale penetrating artery arterioles in the white substance. In this pathology, smooth muscle cells are replaced with fibrohyaline materials, which cause the thickening of blood vessel wall and the contraction of the lumen. Arteriolosclerosis is always immediately identified in leukoaraiosis areas and finally localized ischemic areas, cavities and, just like in leukoaraiosis, diffused rarefaction areas develop Cerebral hemispheric white matter is fed by the long penetrating arteries oriented from the pial network located on the surface of the brain. These tiny arteries go along with the myelinated fibers. The parts of the white matter that neighbours the lateral ventricle walls are fed by the choroidal arteries and subependymal arteries originating from the terminal branches of striate branches. Also having the ventriculofugal qualities, these arteries feed some of the basal ganglions, capsula interna and thalamus. Due to this vascularization pattern, periventricular white substance has been referred as the distal irrigation area easily sensitized to systemic or focal blood stream. Arteriolosclerosis processes as well as increasing elongation and tortuosity in these vessels due to aging become substantial reasons for ischemia in this area [11-15].

In our study, there was a serious correlation between age and leukoaraiosis, as the age increased, the leukoaraiosis stage also increased (**Figure 1**).

Masaw et al. have reported that in patients with advanced stenosis, deep intracerebral arteries are protected by a reduction in the perfusion from the long-term negative results of hypertension and thus a lower rate of atherosclerotic and lipohyalinotik change is observed in the deep arteries in these cases [12]. One of the most important symptoms of generalized atherosclerosis, the increase in intima-media thickness,

may lead to leukoaraiosis. Similar findings have been observed in the studies comparing the findings of de Leeuw et al. Doppler findings and MRI findings [16]. Although the clinical, pathological, the pathophysiological and experimental studies to date demonstrated that the vascular-ischemic originated leukoaraiosis correlates with stroke cases as well as dementia and some stroke risk factors [8,9,12,17,18]. The data related to the frequency of leukoaraiosis were obtained from the various case series with and without neurological findings. When the literature data are reviewed, it is observed that there are studies indicating that previous stroke history is a risk factor for leukoaraiosis [9]. In the Rotterdam study, mild but a non-significant relationship was observed between hypertension and leukoaraiosis [9]. However, for example, the Swedish study [19] suggested that arterial hypertension is an independent risk factor in leukoaraiosis development. Debet and Markus' meta-analysis showed that leukoaraiosis is correlated with increased stroke, dementia and mortality risk [20].

After reviewing the literature considering leukoaraiosis etiopathogenesis, Pantoni and Garcia [21] reported that so many clinical, pathological, physio-pathological and experimental data supports this opinion. The most important contribution to the view that leukoaraiosis originates from ischemic has been made by the results of epidemiologic and clinic studies. The parallelism of leukoaraiosis with the risk factors such as aging, chronic hypertension and diabetes as well as its frequency in the cases of stroke and cognitive impairment due to vascular dysfunction contributes a lot to this opinion [8,10,22]. In our study, there was a significant correlation between leukoaraiosis phase with mild atrophy, severe atrophy and cerebrovascular disease.

In various clinical studies, leukoaraiosis has been shown to be associated with age, hypertension, heart disease and diabetes mellitus [8,9,23-25]. Indeed, leukoaraiosis can be found in a considerable part of the stroke cases [8,11-15,26,27]. When these data are compared with literature data [6,12,26,28] and when the pathogenesis of small artery disease [9] is considered, they have been interpreted as an expected finding. But in their study in 2008, Lee et al. stated that the fact that it is observed mostly in large artery diseases might be due to ethnic differences [29]. The pathological changes occurring in small penetrating arteries in white matter due to chronic hypertension and aging might be causing both small artery disease and leukoaraiosis as a reflection of it. Arteriolosclerosis is the common pathology for both cases. When the ischemic stroke cases are reviewed

according to lesion location, in the light of the above data, leukoaraiosis was most frequently observed in cases with lacunar infarct. The small artery disease in the pathogenesis of lacunar infarct is one of the most important reasons for leukoaraiosis. Similar findings were found by other researchers [30,31]. The LADIS study which ended in 2008 had present vascular risk factors, the leukoaraiosis and lacunars were reported to increase over time, especially in the subcortical white matter [32], however the 2015 study in Korea showed that it increases in cases with large artery disease over time, while the cases that show decrease cannot be correlated with different stroke types [33]. Leukoaraiosis is symptom observable in Alzheimer's disease as well [34-37]. Findings regarding deep and subcortical white matter changes were observed in the MRI of 50-93% of these patients [34]. However, the leukoaraiosis changes in Alzheimer's patients are reported to be milder than the leukoaraiosis in the cases with cerebrovascular diseases [35].

In multiple regression analysis of our study; leukoaraiosis phase associated with age, severe atrophy, mild atrophy, trigeminal neuralgia, and dementia.

Conclusion

Lexical meaning of leukoaraiosis is the decrease of density in white matter. This white matter changes increase through aging in both healthy groups and patients. Although the clinical, pathological, the pathophysiological and experimental studies to date demonstrated that the vascular-ischemic originated leukoaraiosis correlates with stroke cases as well as dementia and some stroke risk factors. The data related to the frequency of leukoaraiosis were obtained from the various case series with and without neurological findings. When the literature data are reviewed, it is observed that there are studies indicating that previous stroke history is a risk factor for leukoaraiosis. As a result, it is noteworthy that leukoaraiosis increases in the geriatric population. A common feature of similar studies is the increased incidence frequency of leukoaraiosis with age.

Funding and Conflict of Interest

The authors have no financial or personal relationships with other people or organizations that could pose a conflict of interest in connection with the present work.

Acknowledgement

This article was presented as an oral presentation in the 13th Çukurova Neurology Days.

References

1. Hachinski VC, Potter P, Merskey H. Leukoaraiosis. *Arch Neurol* 1987; 44: 21-23.
2. Bradley WG, Waluch V, Brant-Zavvadzki M, et al. Patchy, periventricular white matter lesions in the elderly: common observation during NMR imaging. *Noninvasive Med Imaging* 1984; 1: 35-41.
3. Skoog I, Palmertz B, Andreasson LA. The prevalence of white matter lesions on computed tomography of the brain in demented and non-demented 85-year-olds. *Geriatr Psychiatry Neurol* 1994; 7: 169-175.
4. Brant-Zawadzki M, Fein G, Van Dyke C, et al. MR imaging of the aging brain: patchy white-matter lesions and dementia. *Am J Neuroradiol* 1985; 6: 675-682.
5. Goto K, Ishii N, Fukasawa H. Diffuse white-matter disease in the geriatric population: A clinical, neuropathological, and CT study. *Radiology* 1981; 141: 687-695.
6. Kinkel WR, Jacobs L, Pollachini I, et al. Subcortical arteriosclerotic encephalopathy (Binswanger's disease): Computed tomographic, nuclear magnetic resonance, and clinical correlations. *Arch Neurol* 1985; 42: 951-959.
7. Lotz PR, Ballinger WE Jr, Çulsling RG. Subcortical arteriosclerotic encephalopathy: CT spectrum and pathologic correlation. *Am J Neuroradiol* 1986; 7: 817-822.
8. Inzitari D, Diaz F, Fox AF, et al. Vascular risk factors and leuko-araiosis. *Arch Neurol* 1987; 44: 42-47.
9. Breteler MMB, van Swieten JC, Bots ML, et al. Cerebral white matter lesions, vascular risk factors, and cognitive function in a population-based study: The Rotterdam Study. *Neurology* 1994; 44: 1246-1252.
10. Inzitari D. Age-related white matter changes and cognitive impairment. *Ann Neurol* 2000; 47: 141-143.
11. Awad IA, Spetzler RF, Hodak JA, et al. Incidental subcortical lesions identified on magnetic resonance imaging in the elderly, I: correlation with age and cerebrovascular risk factors. *Stroke* 1986; 17: 1084-1089.
12. Hijdra A, Verbeeten B Jr, Verhulst JAPM. Relation of leukoaraiosis to lesion type in stroke patients. *Stroke* 1990; 21: 890-894.
13. Wiszniewska M, Devuyst G, Bogousslavsky J, et al. What is the significance of leukoaraiosis in patients with acute ischemic stroke? *Arch Neurol* 2000; 57: 967-973.
14. Hijdra A, Verbeeten B Jr. Leukoaraiosis and ventricular enlargement in patients with ischemic stroke. *Stroke* 1991; 22: 447-450.
15. Marino JG, Hachinski V. Leukoaraiosis. Reifying rarefaction. *Arch Neurol* 2000; 57: 925-926.
16. Erik de Lecuw, Jan Cees de Graf. Carotid atherosclerosis and cerebral white matter lesions. *J.Neurol* 2000; 247: 291-296
17. Inzitari D, Cadelo M, Marranci ML, et al. Vascular deaths in elderly neurological patients with leukoaraiosis. *J Neurol Neurosurg Psychiatry* 1997; 62: 177-181.
18. Bruin A, Englund E. A white matter disorder in dementia of the Alzheimer type: a pathoanatomical study. *Ann Neurol* 1986; 19 :253-262.
19. Lindgren A, Roijer A, Rudling O, et al. Cerebral lesions on magnetic resonance imaging, heart disease and vascular risk factors in subjects without stroke: A population-based study. *Stroke* 1994; 25: 929-934.
20. Debette S, Markus HS. The clinical importance of white matter hyperintensities on brain magnetic resonance imaging: systematic review and meta-analysis. *BMJ* 2010; 341: c3666.
21. Pantoni L, Garcia JH. Pathogenesis of leukoaraiosis. A review. *Stroke* 1997; 28: 652-659.
22. Inzitari D, Giordano GP, Ancona AL, et al. Leukoaraiosis, intracerebral hemorrhage, and arterial hypertension. *Stroke* 1990; 21: 1419-1423.
23. Leys D, Pasquier F, Parnetti L. Epidemiology of vascular dementia. *Haemostasis* 1998; 28: 134-150.
24. Longstreth Jr WT, Manolio TA, Arnold A, et al. Clinical correlates of white matter findings on cranial magnetic resonance imaging of 3301 elderly people. The Cardiovascular Health Study. *Stroke* 1996; 27: 1274-1282.
25. Lindgren A, Roijer A, Rudling O, et al. Cerebral lesions on magnetic resonance imaging, heart disease and vascular risk factors in subjects without stroke: A population-based study. *Stroke* 1994; 25: 929-934.
26. Gerard G, Weisberg LA. MRI periventricular lesions in adults. *Neurology* 1986; 36: 998-1001.
27. Hershey LA, Modio MT, Greenough PG, et al. Magnetic resonance imaging in vascular dementia. *Neurology* 1987; 37: 29-36.
28. Mandybur TL. The incidence of cerebral amyloid angiopathy in Alzheimer's disease. *Neurology* 1975; 25: 120-126.
29. Lee SJ, Kim JS, Lee KS, et al. The leukoaraiosis is more prevalent in the large artery atherosclerosis stroke subtype among Korean patients with ischemic stroke. *BMC Neurol* 2008; 8: 31.

30. Bogousslavsky J, Regli F, Uske A. Leukoencephalopathy in patients with ischemic stroke. *Stroke* 1987; 18: 896-899.
 31. Lindgren A, Roijer A, Rudling O, et al. Cerebral lesions on magnetic resonance imaging, heart disease and vascular risk factors in subjects without stroke: A population-based study. *Stroke* 1994; 25: 929-934.
 32. Gouw AA, van der Flier WM, Fazekas F, et al. LADIS Study Group. *Stroke* 2008; 39: 1414-1420.
 33. Cho AH, Kim HR, Kim W, et al. White matter hyperintensity in ischemic stroke patients: it may regress over time. *Stroke* 2015; 17: 60-66.
 34. Brant-Zawadzki M, Fein G, Van Dyke C, et al. MR imaging of the aging brain: patchy white-matter lesions and dementia. *Am J Neuroradiol* 1985; 6: 675-682.
 35. Bruun A, Englund E. A white matter disorder in dementia of the Alzheimer type: a pathoanatomical study. *Ann Neurol* 1986; 19 :253-262.
 36. Rezek DL, Morris JC, Fulling KH, et al. Periventricular white matter lucencies in senile dementia of the Alzheimer type and in normal ageing. *Neurology* 1987; 37: 1365-1368.
 37. Fazekas F, Chavvuk JB, Alavi A, et al. MR signal abnormalities at 1.5 T in Alzheimer's dementia and normal aging. *Am J Neuroradiol* 1987; 8: 421-426.
-

This manuscript was peer-reviewed
Mode of Review: Single-blinded
Academic Editor: Dr. Ruqaiyah Khan