



Concurrent Isolated Hypoglossal Nerve Palsy Induced by Jugular Vein Thrombosis, Cervical Plexus Masses, and Vestibular Schwannoma: A Complex Case Report Highlighting Anatomical Pathways and Clinical Challenges

Sara Zarei^{1*}, Christopher Khatchadourian², Bijan Bonakdar², Andrew Comer², Sara Hassani³, Diana Abdul Rahman¹, Rojeen Zarei⁴ and Sadiq Altamimi¹

¹ Department of Neurology, The Neurology Group Institution, Pomona, CA, USA

² College of Osteopathic Medicine of the Pacific, Department of Medicine, Western University of Health Sciences, CA, USA

³ Perelman School of Medicine, University of Pennsylvania, PA, USA

⁴ Department of Biology, University of Arizona, Tucson, Arizona, USA

ARTICLE INFO

Received 30 August 2023

Revised 25 September 2023

Available Online 01 Oct 2023

*CORRESPONDING AUTHOR

Dr. Sara Zarei, Department of Neurology, The Neurology Group Institution, Pomona, CA, USA

ABSTRACT

Background: Hypoglossal nerve palsy is typically observed alongside other cranial nerve impairments, with isolated cases being infrequent and posing diagnostic complexities. Originating intracranially, the nerve traverses the skull and neck, governing tongue motility. Lesions are classified as supranuclear, nuclear, or infranuclear, engendering tongue deviation towards the affected side. Due to its proximity to crucial structures, hypoglossal nerve palsy often coincides with supplementary symptoms. Etiologies encompass skull base metastases, carotid artery pathologies, and trauma. This study explores less conventional triggers such as hypoglossal nerve palsy following thyroidectomy, jugular vein thrombosis, cervical plexus masses, and Vestibular Schwannoma.

Case Description: A 38-year-old female presented to the Neurology outpatient clinic with leftward tongue deviation and left-sided neck and shoulder pain accompanied by stiffness that had begun several months prior. In addition to the tongue deviation, she reported minor dysphagia, blurry vision, and intermittent numbness on the left side of her scalp. MRI and duplex ultrasound verified the presence of left internal jugular vein (IJV) thrombosis. The patient was initially prescribed Eliquis and acetazolamide, with slight improvements in symptoms, though medication use ceased due to side effects. During a subsequent follow-up visit, persistent tongue deviation and worsening left shoulder pain prompted additional cervical imaging. A new cervical spine MRI revealed a 15x14 mm nodular dural enhancement with a paraspinal soft tissue mass at the C2 level. Concurrently, multiple cranial nerve palsies were detected during the physical examination. Unfortunately, the patient was subsequently diagnosed with breast cancer. To rule out brain metastases related to her breast cancer, an additional brain MRI was performed, revealing a newly formed 2.3x1.6x1.2 cm left cerebellopontine angle mass adjacent to the internal auditory canal (IAC), suggestive of a vestibular schwannoma but without evidence of metastatic disease. The patient's care involved a multidisciplinary team, including hematologist-oncologists, neurosurgeons, and neurologists.

Conclusion: This case report highlights the less common causes of hypoglossal nerve palsy, such as jugular vein thrombosis, cervical plexus masses, and Vestibular Schwannoma. The persistence of the patient's palsy is attributed to the cumulative impact of these anatomical factors on the hypoglossal nerve. This underscores the diagnostic challenges posed by isolated hypoglossal nerve palsy and emphasizes the importance of comprehensive clinical evaluation and imaging for accurate diagnosis.

Keywords: *Hypoglossal Nerve Palsy; Vestibular Schwannoma; Jugular vein thrombosis; Internal auditory canal; Cranial nerve.*

Background

The hypoglossal nerve (cranial nerve XII) delivers motor innervation to all intrinsic and extrinsic muscles of the tongue except for the palatoglossus muscle, which receives motor innervation from cranial nerve X, the vagus nerve. Hypoglossal nerve palsy is frequently accompanied by other cranial nerve manifestations, such as facial nerve paralysis and ophthalmic symptoms. However, isolated hypoglossal nerve palsy is relatively uncommon and poses a diagnostic challenge.

Anatomically the hypoglossal nerve is divided into intracranial and extracranial portions. Intracranially, it originates from the medulla oblongata as small fibers and merges into two trunks, where it then exits the skull via the hypoglossal canal located at the base of the skull. At this juncture, the extracranial portion of the nerve begins. The nerve travels initially to the lateral prominence of the anterior surface of C1 transverse process, where it then descends between the internal carotid artery and internal jugular vein. Once the nerve reaches the angle of the mandible, it travels anteriorly and deep to the posterior belly of the digastric muscle, subsequently dividing into numerous fibers as it enters the mouth [1]. Hence lesions of the hypoglossal nerve can be categorized into three groups: supranuclear, nuclear, and infranuclear, based on their location. Injuries to the hypoglossal nerve result in the tongue deviating toward the weakened side.

Based on MRI studies, it has been determined that definite ipsilateral hypoglossal paresis occurs in around 3% of patients [2]. Hypoglossal nerve palsy (HNP) is not an uncommon neurological phenomenon. Its prevalence as an isolated palsy, however, is exceedingly rare and warrants investigation along the peripheral path of the nerve to rule out underlying causes [3].

Because of its proximity to important anatomical structures, additional symptoms are expected in

conjunction with HNP, such as signs of disease of the medulla oblongata, the site of the nerve's origin. Some common causes of HNP include metastases to the base of the skull, internal carotid artery aneurysm or dissection, dural arteriovenous fistulas, posterior fossa arachnoid cysts, atlanto-occipital joint synovial cysts, and trauma-induced HNP [3]. The principal objective of this case report is to explore the less prevalent causes of HNP, conditions that often pose diagnostic challenges. These include occurrences of HNP following thyroidectomy, jugular vein thrombosis, the presence of cervical plexus masses, and the manifestation of Vestibular Schwannoma.

Case Description

A 38-year-old female presented to the Neurology outpatient clinic with a history of left-sided neck and shoulder pain, along with stiffness. She also reported experiencing leftward tongue deviation over the past couple months, accompanied by recent minor dysphagia, blurry vision, and intermittent numbness in the left side of her scalp. Her only past medical history included thyroid cancer status-post thyroidectomy with radiation therapy 20 years ago. The patient's medications included levothyroxine sodium 125 mg and a vitamin D oral supplement. Her neck and shoulder stiffness had been present for five months and she noted tongue deviation beginning a couple months ago. The patient was seen by her primary care physician and given the persistence of her symptoms, was referred to our outpatient Neurology clinic.

The patient's vital signs were within normal parameters. On physical examination, subtle pallor and localized edema were observed in the left arm and neck regions with no detection of neck masses. No disparities in pulse rhythm or quality were discerned between the right and left extremities. Additionally, there were no indications of delay in radial pulses or between the radial and

femoral pulses. On neurological examination, the patient showed normal consciousness and orientation. Cranial nerves exhibited intact function except for palsy in CN XII. Mild muscle weakness and sensory deficit in the left arm and leg were detected. Motor function assessment revealed that, upon attempting to elevate her left arm beyond shoulder level, the patient exhibited notable weakness. Furthermore, she experienced difficulty in executing a controlled descent of the arm, as it exhibited an inclination to descend abruptly rather than a controlled and gradual lowering. Ataxia was not detected in any of the limbs and trunk. No other abnormalities were noted on physical exam. She denied diplopia, vertigo, facial numbness, weakness, and slurred speech. Brain MRI without contrast was

unremarkable with no other acute intracranial changes. Lab results revealed very slight elevation in ESR (35 mm/hr; reference: <32) and slightly decreased vitamin D (27.2 ng/ml; reference: 30.0-100.0).

MRI of the cervical spine showed left Internal Jugular Vein (IJV) thrombus versus lymphadenopathy, and an asymmetrical left occipital vein at the level of C1-2 (Figure 1B). There was no significant facet or disc disease and no canal or foraminal stenosis. A duplex venous ultrasound confirmed left IJV thrombus, with no thrombus seen in the left subclavian, axillary, brachial, basilic, or cephalic veins (Figure 1A). She was started on Eliquis and acetazolamide.

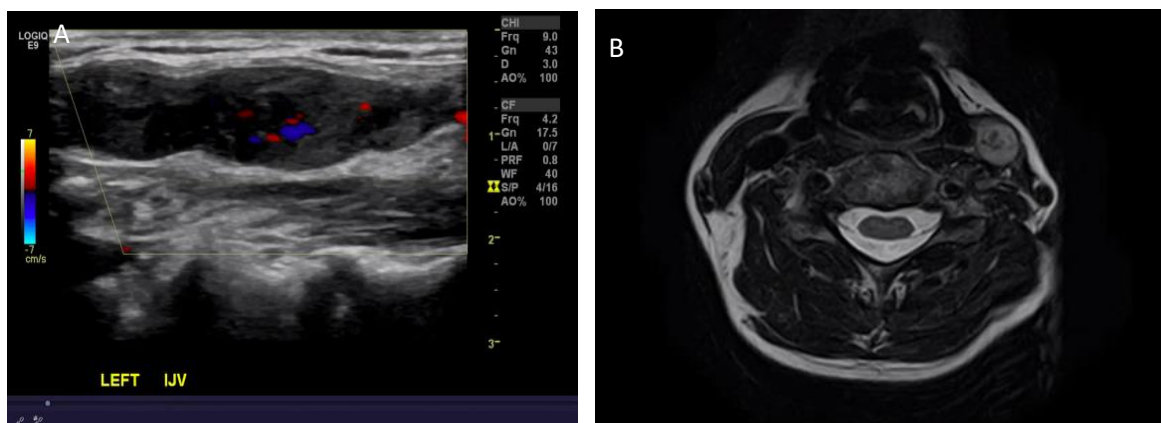


Figure 1A: Color Doppler Ultrasound of the left Internal Jugular Vein (IJV) shows a hyperechoic thrombus within the IJV which fills the lumen and diminishes the normal color Doppler vascularity of the vein—**Figure 1B:** demonstrates an absence of normal flow void on the left IJV. The clot is isointense to hyperintense on T2 weighted image.

A few months later during a follow up visit, the patient complained of left sided hearing loss, left facial paralysis and numbness of the left anterior upper chest. Labs including comprehensive metabolic panel were within normal limits. She reported stopping the medications after 2 months of use due to their side effects. Persistent tongue deviation and concurrent multiple cranial nerve palsies were detected during the physical examination. These symptoms prompted additional cervical imaging. A new cervical spine MRI revealed a 15x14 mm nodular dural enhancement with a paraspinal soft tissue mass at the C2 level (Figure 2).

Brainstem auditory evoked response (BAER) study was abnormal, showing poorly formed waveform on the left and prolonged wave absolute latency on the left as well as peripheral left-sided acoustic neuropathy. Visual evoked potential was within normal limits.

Unfortunately, the patient was subsequently diagnosed with breast cancer and was referred to a Hematologist / Oncologist.

To rule out brain metastases related to her breast cancer, an additional brain MRI was performed, revealing a newly formed 2.3x1.6x1.2 cm left cerebellopontine angle mass adjacent to the internal auditory canal (IAC), suggestive of a vestibular schwannoma but without evidence of metastatic disease. She continued to experience tongue deviation along with intermittent dysphagia. PET scan did not reveal any metastatic disease. The patient was referred to neurosurgery and, after almost a year, continues to be followed by a multidisciplinary team consisting of haematology / oncology, neurosurgery and neurology.

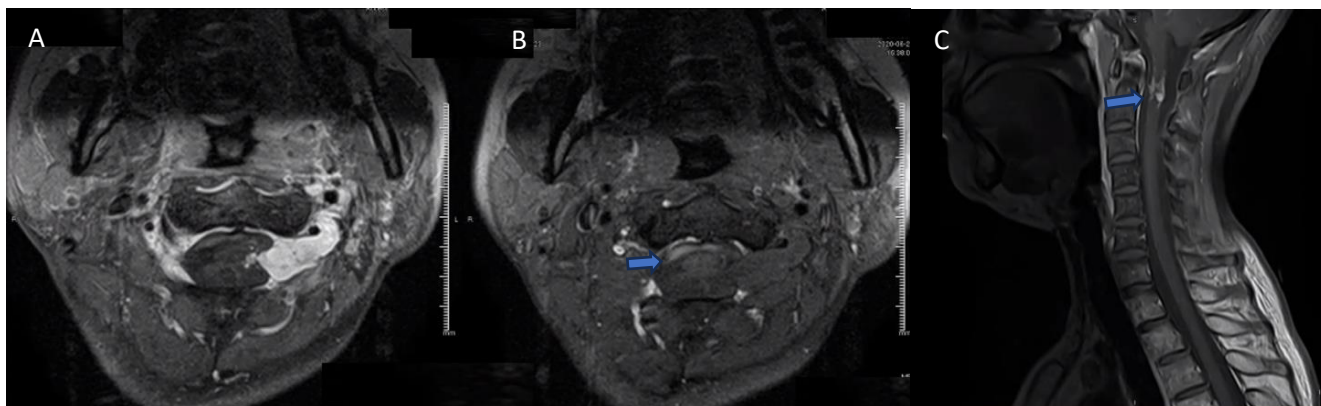


Figure 2: Demonstrates a nodular intradural extramedullary mass-like lesion at the C2 level measuring 15 mm in transverse diameter and 14 mm in craniocaudal diameter extending to the left neural foramen, which is isointense on T1 weighted image as seen in Figure 2.A with abnormal heterogeneous intense enhancement on T1 C+ (Gd) at an axial and sagittal plain as seen in Figure 2. B, and 2. C, respectively, concerning for metastasis.

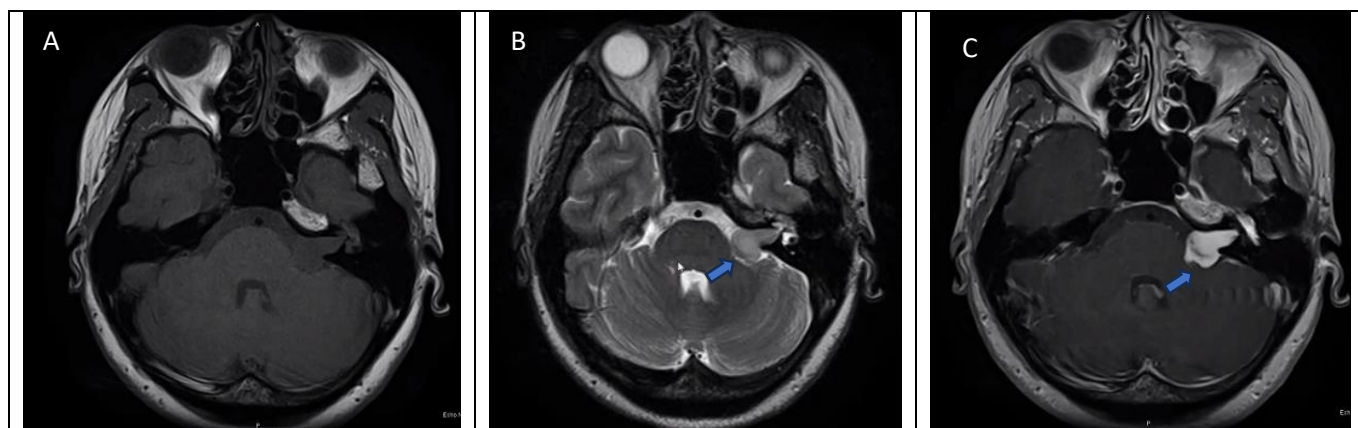


Figure 3: Demonstrates a well-circumscribed mass-like lesion that displaces adjacent structures without direct invasion at the left Cerebellopontine angle (CP angle) with extension to the left auditory canal measuring 23*16*12 mm, which is isointense to mildly hypointense to the adjoining brain on T1 weighted imaging as seen in Fig 3. A, mildly hyperintense and heterogenous to the adjacent brain on T2 weighed imaging as seen in Fig 3. B, intensely hyperintense and homogeneous on T1 C+ (Gd) as seen in Fig 3. C.

Discussion

The core objective of this case report is to delve into the less common causes of hypoglossal nerve palsy, including jugular vein thrombosis, the presence of cervical plexus masses, and Vestibular Schwannomas. Furthermore, this report seeks to accentuate the anatomical pathways impacted by each of these conditions on the hypoglossal nerve, while also shedding light on the clinical complexities inherent to these scenarios.

The patient in this case had a thyroidectomy year prior to her onset of her HNP symptoms. Most cases of

postoperative HNP following thyroidectomy occurred on the first post-operative day. However, cases of HNP a few hours following thyroidectomy have been reported as well [1]. No cases of delayed onset HNP following thyroidectomy are known to the authors. Consequently, in the present case, the isolated hypoglossal nerve palsy experienced by the patient is not attributed to the thyroidectomy she underwent several years prior to her symptom's initiation. The hypoglossal nerve courses at the anterior cervical region, terminating at the lateral roots of the tongue. Thus, operations requiring deviation of the neck, oropharynx, or tongue, including bronchoscopy, laryngeal mask airway placement, laryngoscopy, and

oro-tracheal intubation can place the hypoglossal nerve at risk for injury. This has been proposed as a mechanism for injury of the hypoglossal nerve during thyroidectomy but can also indicate potential for HNP in any surgery where the aforementioned techniques are utilized [1].

Careful positioning of the neck to avoid hyperflexion and endotracheal tube malposition, both during thyroidectomy and cervical surgery, can help minimize the risk of iatrogenic HNP. Permanent HNP has been reported among multiple cases of cervical operations at the C2/3 level, thus proving an unfavorable recovery in some patients [4].

Given the course of the hypoglossal nerve next to the internal jugular vein (IJV), jugular vein thrombosis may also induce HNP. In the context of hypoglossal nerve palsy, the anatomical proximity of the hypoglossal nerve to the internal jugular vein can make it susceptible to compression or irritation by the thrombosed vein. Additionally, localized inflammation and edema resulting from the thrombotic process may lead to nerve compression or compromise its blood supply, contributing to nerve dysfunction and subsequent palsy. This scenario has been described previously in a case of cranial nerve 9-12 palsy in a patient with internal jugular vein thrombosis [5].

IJV thrombosis frequently arises as a complication of various factors, including head and neck infections, surgical procedures involving the local skin and throat, trauma, both local and distant malignancies, placement of central venous catheters, polycythemia vera, intravenous drug misuse, neck massage, ovarian hyperstimulation syndrome, and hypercoagulable states due to conditions like factor V Leiden, protein C deficiency, protein S deficiency, anti-phospholipid syndrome, and anti-thrombin III deficiency. Moreover, IJVT can also manifest as a primary pathological process [6].

In this particular case, the precise etiology of IJV thrombosis remained elusive. Nevertheless, the patient's initial presentation was characterized by the gradual onset of neck and shoulder pain accompanied by stiffness, which progressively intensified and ultimately culminated in the development of tongue deviation. The patient's preliminary symptoms align with those conventionally associated with thrombosis of the internal jugular vein. Subsequently, the persistent compression exerted by the internal jugular thrombus

upon the hypoglossal nerve led to the development of leftward deviation of the tongue.

Furthermore, the hypoglossal nerve exits the hypoglossal canal, located at the base of the skull, and travels inferiorly within the carotid sheath. It then courses between the internal carotid artery and internal jugular vein as it passes anterior to C1/C2. The hypoglossal nerves then course medially as they descend down to the level of C2/3, making the nerves susceptible to injury via anterior cervical approach at this cervical spinal level. Accordingly, Iatrogenic HNP has been commonly reported during anterior cervical surgery, particularly between the levels of C2 and C3 [4]. Additionally, the ansa cervicalis, which originates from the anterior branches of C1, C2 and C3, loops with the hypoglossal nerve with C1 providing a branch to the hypoglossal nerve [7]. According to this anatomic relationship between the cervical plexus and the hypoglossal nerve and the feasibility of HNP from anterior superior cervical approaches, it may be plausible for masses on the cervical plexus, likely from metastases, to induce HNP.

Schwannomas are benign, slow growing tumors of the myelin sheath of peripheral nerves, representing 35% of head and neck tumors, 30% of primary spinal tumors, and very rarely in the craniocervical region [8] [9]. Specifically, vestibular schwannomas (acoustic neuroma) are benign tumor growths of the vestibulocochlear nerve (cranial nerve VIII) and are considered the most common nonmalignant nerve sheath tumor for schwannoma development [10].

Due to its slow growing nature, neurological signs and symptoms of schwannomas are difficult to detect and diagnosis is usually made after advanced tumor growth. Clinically, schwannomas are relatively asymptomatic when the tumor is less than 1-2cm in diameter; at 2-3cm, patients may experience pain and paresthesia. At 4-5cm, schwannomas may cause compression and dislocation (without infiltration) of the nerve root, with specific functional deficits that can elucidate the origin of the nerve involved [9]. Common clinical signs of a vestibular schwannoma, include hearing loss, tinnitus, disequilibrium, and vertigo [10].

Surgical removal of a large schwannoma involving the ventral ramus of C2 via a posterior approach using craniectomy and C1/2 laminectomy induced HNP in conjunction with mild hemiparesis [8]. To the authors' knowledge, however, no publications about HNP directly from a vestibular schwannoma have been cited.

Citation: Zarei S, Khatchadourian C, Bonakdar B, et al. Concurrent Isolated Hypoglossal Nerve Palsy Induced by Jugular Vein Thrombosis, Cervical Plexus Masses, and Vestibular Schwannoma: A Complex Case Report Highlighting Anatomical Pathways and Clinical Challenges. *J Neurol Neurosurg Psychiatry Res* 2023; 5(1): 110. doi: [10.31531/edwiser.jnnpr.1000110](https://doi.org/10.31531/edwiser.jnnpr.1000110)

Notably, this patient's enduring hypoglossal nerve palsy is a result of the cumulative impact of these conditions, as elucidated by the anatomical etiologies delineated here. This persistence underscores the critical importance of acknowledging the collective influence of these anatomical factors on the hypoglossal nerve.

Conclusion

In conclusion, this case report has shed light on the less common causes of hypoglossal nerve palsy, including jugular vein thrombosis, the presence of cervical plexus masses, and the emergence of Vestibular Schwannoma. Each of these conditions impacts the anatomical pathways of the hypoglossal nerve, leading to the clinical complexities observed in these scenarios.

It is noteworthy that this patient's hypoglossal nerve palsy persisted because each of these conditions contributed to the pathology due to the anatomical etiologies discussed in this paper. The persistence of the palsy underscores the importance of recognizing the cumulative effect of these anatomical factors on the hypoglossal nerve. Notably, HNP is a relatively rare condition, and isolated HNP even more so. It often poses diagnostic challenges due to its diverse etiologies and varied clinical presentations. The examination of such cases, as presented here, underscores the importance of a thorough clinical evaluation and imaging studies to pinpoint the underlying cause accurately.

This case report contributes to the broader knowledge of hypoglossal nerve palsy, offering clinicians a comprehensive perspective on the diverse etiologies and clinical manifestations of this condition. It underscores the importance of a meticulous diagnostic approach, collaboration among specialists, and ongoing research to enhance our ability to manage and treat HNP effectively.

Patient Consent Declaration

Authors hereby declare that they have obtained patient consent.

Conflict of Interest

None.

Funding

None to declare.

References

1. Bshait MB, Alyami H, Al-Osail E, Al Arfaj H. Ipsilateral hypoglossal nerve palsy following left hemithyroidectomy: case report and review of literature. *International journal of surgery case reports*. 2018 Jan 1;51:5-7.
2. Kim JS, Caplan LR. Vertebrobasilar disease. *InStroke* 2016 Jan 1 (pp. 413-448). Elsevier.
3. Lemound J, Papadimas D, Skodda S, Tannapfel A, Alekseyev A, Kunkel M. Isolated Hypoglossal Nerve Palsy as an Early Symptom of a Granular Cell Tumor. *International Journal of Environmental Research and Public Health*. 2022 Feb 25;19(5):2690.
4. Ames CP, Clark AJ, Kanter AS, Arnold PM, Fehlings MG, Mroz TE, Riew KD. Hypoglossal nerve palsy after cervical spine surgery. *Global spine journal*. 2017 Apr;7(1_suppl):37S-9S.
5. Neo S, Lee KE. Collet-Sicard syndrome: a rare but important presentation of internal jugular vein thrombosis. *Practical Neurology*. 2017 Feb 1;17(1):63-5.
6. Scerrati A, Menegatti E, Zamboni M, Malagoni AM, Tessari M, Galeotti R, Zamboni P. Internal jugular vein thrombosis: etiology, symptomatology, diagnosis and current treatment. *Diagnostics*. 2021 Feb 23;11(2):378.
7. Glenesk NL, Kortz MW, Lopez PP. Anatomy, head and neck, posterior cervical nerve plexus. *InStatPearls [Internet]* 2022 Jul 25. StatPearls Publishing.
8. Kabatas S, Cansever T, Yilmaz C, Demiralay E, Celebi S, Caner H. Giant craniocervical junction schwannoma involving the hypoglossal nerve: case report. *Turkish Neurosurgery*. 2010 Jan 1;20(1).
9. Fornaro R, Salerno A, Filip DC, Caratto E, Caratto M, Casaccia M. Schwannoma of the hypoglossal nerve: review of the literature based on an illustrative case. *Molecular and clinical oncology*. 2017 Aug 1;7(2):288-94.
10. Cioffi G, Yeboa DN, Kelly M, Patil N, Manzoor N, Greppin K, Takaoka K, Waite K, Kruchko C, Barnholtz-Sloan JS. Epidemiology of vestibular schwannoma in the United States, 2004–2016. *Neuro-Oncology Advances*. 2020 Jan;2(1):vdaa135.
11. Smith K, "Elsevier Encyclopedia of The Neurological Sciences, Second Edition," Elsevier, vol. Second Edition, May 2014.
12. Akhil Sharma, Fazal Raziq, Tyler Kemnic, Rohan Prasad. Phrenic nerve palsy following radiation therapy for patient with breast cancer. 1 *An*

Citation: Zarei S, Khatchadourian C, Bonakdar B, et al. *Concurrent Isolated Hypoglossal Nerve Palsy Induced by Jugular Vein Thrombosis, Cervical Plexus Masses, and Vestibular Schwannoma: A Complex Case Report Highlighting Anatomical Pathways and Clinical Challenges.* *J Neurol Neurosurg Psychiatry Res* 2023; 5(1): 110. doi: [10.31531/edwiser.jnnpr.1000110](https://doi.org/10.31531/edwiser.jnnpr.1000110)

Expanded Role for the Medical Assistant in Primary
Care: Evaluating a Training Pilot. 2021:110.

Copyright: ©2023 Zarei S, et al. This article is distributed under the terms of the Creative Commons Attribution 4.0 International License (<http://creativecommons.org/licenses/by/4.0/>), which permits unrestricted use, distribution, and reproduction in any medium, provided you give appropriate credit to the original author(s) and the source, provide a link to the Creative Commons license, and indicate if changes were made.

